



## Topical mitomycin-C reduced number of myofibroblasts in healing anoplasty wounds in Wistar rats



Harsali Fransiscus Lampus<sup>a,\*</sup>, Suryani As'ad<sup>b</sup>, Rahmawati Minhajat<sup>c</sup>, Warsinggih<sup>d</sup>, Mochammad Hatta<sup>e</sup>, Rina Masadah<sup>f</sup>, Akhmad Makhmudi<sup>g</sup>, Rosdiana Natzir<sup>h</sup>, Wardihan Sinrang<sup>i</sup>, Fachruddin Benyamin<sup>j</sup>, Agussalim Bukhari<sup>b</sup>, Nathania Wonoputri<sup>k</sup>, Nita Mariana<sup>l</sup>, Tommy Rubiyanto Habar<sup>l</sup>

<sup>a</sup> Division of Pediatric Surgery, Department of Surgery, Faculty of Medicine, Universitas Sam Ratulangi, Prof. Dr. R. D. Kandou General Hospital Manado, Indonesia

<sup>b</sup> Department of Clinical Nutrition, Faculty of Medicine, Universitas Hasanuddin, Makassar, Indonesia

<sup>c</sup> Department of Histology, Faculty of Medicine, Universitas Hasanuddin, Makassar, Indonesia

<sup>d</sup> Department of Surgery, Faculty of Medicine, Universitas Hasanuddin, Makassar, Indonesia

<sup>e</sup> Molecular Biology and Immunology Laboratory, Faculty of Medicine, Universitas Hasanuddin, Makassar, Indonesia

<sup>f</sup> Department of Pathology Anatomy, Faculty of Medicine, Universitas Hasanuddin, Makassar, Indonesia

<sup>g</sup> Department of Pediatric Surgery, Faculty of Medicine, Universitas Gadjah Mada, Yogyakarta, Indonesia

<sup>h</sup> Department of Biochemistry, Faculty of Medicine, Universitas Hasanuddin, Makassar, Indonesia

<sup>i</sup> Department of Physiology, Faculty of Medicine, Universitas Hasanuddin, Makassar, Indonesia

<sup>j</sup> Department of Internal Medicine, Faculty of Medicine, Universitas Hasanuddin, Makassar, Indonesia

<sup>k</sup> Department of Child Health, Siloam Hospitals Manado, Manado, Indonesia

<sup>l</sup> Department of Pediatric Surgery, Faculty of Medicine, Universitas Hasanuddin, Makassar, Indonesia

### ARTICLE INFO

#### Keywords:

Topical mitomycin-C

Myofibroblasts

α-SMA

Anoplasty

### ABSTRACT

**Background:** Mitomycin-C (MMC) has been used for treating stricture. Topical MMC has been proven to inhibit fibroblasts proliferation and reduce the number of fibroblasts. Myofibroblasts are originally from fibroblasts. The scarring potential of myofibroblasts has been documented in many anatomical sites. The purpose of this study is to analyze the effect of topical MMC on myofibroblasts in healing anoplasty wounds in Wistar rats.

**Methods:** An anoplasty procedure was performed on Wistar rats (n=30) that were subsequently randomly placed into two equal groups; i.e., control and treated groups. In the treated group, topical mitomycin-C was applied to the wound following the anoplasty procedure. Five rats in each group were weekly sacrificed. The myofibroblasts in tissue samples were identified by immunohistochemical analysis of alpha-smooth muscle actin. The total of myofibroblasts was evaluated by scoring methods. The Mann-Whitney test was used to analyze the statistical significance of differences, and p values below 0.05 were considered to be significant.

**Results:** The median myofibroblasts scores in the first week for the treated and control groups were 5 and 9, respectively. In the second and third week, the median myofibroblasts scores were 6 for both groups. Statistical evaluations revealed significant differences between the groups only in the first week (p=0.007).

**Conclusions:** Topical MMC reduced the myofibroblasts in the first week of healing anoplasty wounds in Wistar rats.

### 1. Introduction

Mitomycin-C (MMC) is a chemotherapeutic agent that has been used as a topical medicine in stricture management at various sites, such as eyes, upper respiratory tract, esophagus, urethra, vagina, and anus for the last three decades [1–12]. For instance, Mueller et al., reported that a single anal dilatation under sedation followed by a single topical

application of MMC for the management of anal stricture showed increased anal diameter and improvements in defecation for all ten pediatric patients [11].

Topical MMC can also act as anti-fibrotic agent, as it has been proven to inhibit fibroblasts proliferation [6,7,10,12]. A study conducted by Lee [10] showed that MMC inhibited rabbit and human subconjunctival fibroblasts proliferation without affecting their

\* Corresponding author.

E-mail addresses: [drharsali@gmail.com](mailto:drharsali@gmail.com), [harsali.f.lampus@gmail.com](mailto:harsali.f.lampus@gmail.com) (H.F. Lampus).

<https://doi.org/10.1016/j.wndm.2019.100154>

Received 10 October 2018; Received in revised form 2 April 2019; Accepted 25 April 2019

Available online 26 April 2019

2213-9095/ © 2019 Elsevier GmbH. All rights reserved.

migration or attachment [10]. An *in vitro* study using MMC on normal dermal fibroblasts showed that the fibroblasts proliferation was significantly decreased in a period of ten days [13].

The myofibroblasts are a specifically differentiated fibroblasts which are characterized by the expression of alpha-smooth muscle actin ( $\alpha$ -SMA). The differentiated myofibroblasts are characteristic of contracting granulation tissue in an open wound as well as practically all fibrocontractive disease. The transition from fibroblasts to myofibroblasts is influenced by mechanical stress, transforming growth factor beta 1 (TGF- $\beta$ 1), and cellular fibronectin. Myofibroblasts will disappear by apoptosis when epithelialization occurs [14–16]. Myofibroblasts are the primary extracellular matrix secreting cells (e.g., collagen type I and III) during wound healing and fibrosis, and are mainly responsible for the contractility of scar tissue as it matures [17]. The scarring potential of myofibroblasts has been documented in many anatomical sites throughout the body [16].

In our previous study, we observed a significant decrease in the number of fibroblasts in the MMC treated group compared with the control group [18]. As myofibroblasts are originated from fibroblasts, then the suppression of fibroblasts proliferation should result in a decrease in myofibroblasts. Kim et al. have shown that the application of MMC would lead to reduced keratocyte density due to increased keratocyte apoptosis and the limited number of myofibroblasts within the wound [12,19]. Could the significant decrease in fibroblasts lead to myofibroblasts reduction as well? This study was conducted to analyze the effect of topical MMC on myofibroblasts in healing anoplasty wounds in Wistar rats.

## 2. Methods

This is an experimental study that sought to analyze the effect of topical MMC on myofibroblasts in healing anoplasty wounds in Wistar rats. Wistar male rats (control and treated groups; 15 rats each) were used as the animal model to examine the effect of topical MMC on myofibroblasts in anoplasty due to the similarity of their anal structures with those of human [20,21]. Two weeks of adaptation periods in the animal laboratory were allocated to all rats before they had the anoplasty procedure.

The anoplasty wounds were created via 5 mm deep circumferential incision at the anal verge that was extended until the anal sphincter muscle was located followed by the placement of absorbable interrupted sutures (Fig. 1A). All animals were anesthetized by the intramuscular administration of 50 mg ketamine. For the treated groups, a diluted MMC solution at a concentration of 0.5 mg/mL was applied with a cotton swab that was placed for 5 min over the entire anoplasty wound for every sample (Fig. 1B), while the control groups did not receive such treatment. All samples were provided with the same wound care management for the first seven days. Wound care management with 3% povidone-iodine was administered twice per day, once in the morning and afternoon. Oral antibiotics and analgesics were given to every sample (Fig. 1C). On the 7th day (first week), 14th day (second week), and 21st day (third week) after the anoplasty procedures, five rats in each group were sacrificed, and biopsies were taken for the immunohistopathological examination using avidin-biotin peroxidase complex method (Fig. 1D) [18].

The immunohistopathological examinations were performed by a qualified pathologist. The myofibroblasts in tissue samples were identified by  $\alpha$ -SMA monoclonal antibody (GT $\times$ 100034, GeneTex Inc., Irvine, California, the working dilution 1:100). The  $\alpha$ -SMA expression in immunohistopathological examinations was shown as a light to dark brown staining at the cytoplasm in microscopic fields at 400x magnification. The total of myofibroblasts was determined by a modified scoring system based on the intensity and the percentage of the staining area (Table 1) [22].

Statistical analyses were performed using Mann-Whitney tests. Differences between the treated and control groups were considered

significant when  $p < 0.05$ . This study was approved by the Health Research and Ethics Committee of Medicine Faculty, Hasanuddin University, Makassar, Indonesia.

## 3. Results

The anoplasty wound of all samples in both groups had been macroscopically healed by the first week after the surgical procedure. The myofibroblasts scores for both groups during three weeks observation are shown in Table 2. The median score of myofibroblasts in the first week for the treated and control groups were 5 and 9, respectively. In the second and third week, the median myofibroblasts scores for both groups were 6. Statistical evaluations revealed significant differences between the groups only in the first week ( $p = 0.007$ ).

Representative images of the immunohistopathological evaluations of the treated and control groups are shown in Fig. 2. Significant differences of the  $\alpha$ -SMA expression in immunohistopathological examinations between the treated and control groups were observed in the first week. The lowest  $\alpha$ -SMA expression (score 5) was identified in the treated group, while the highest  $\alpha$ -SMA expression (score 9) was observed in the control group.

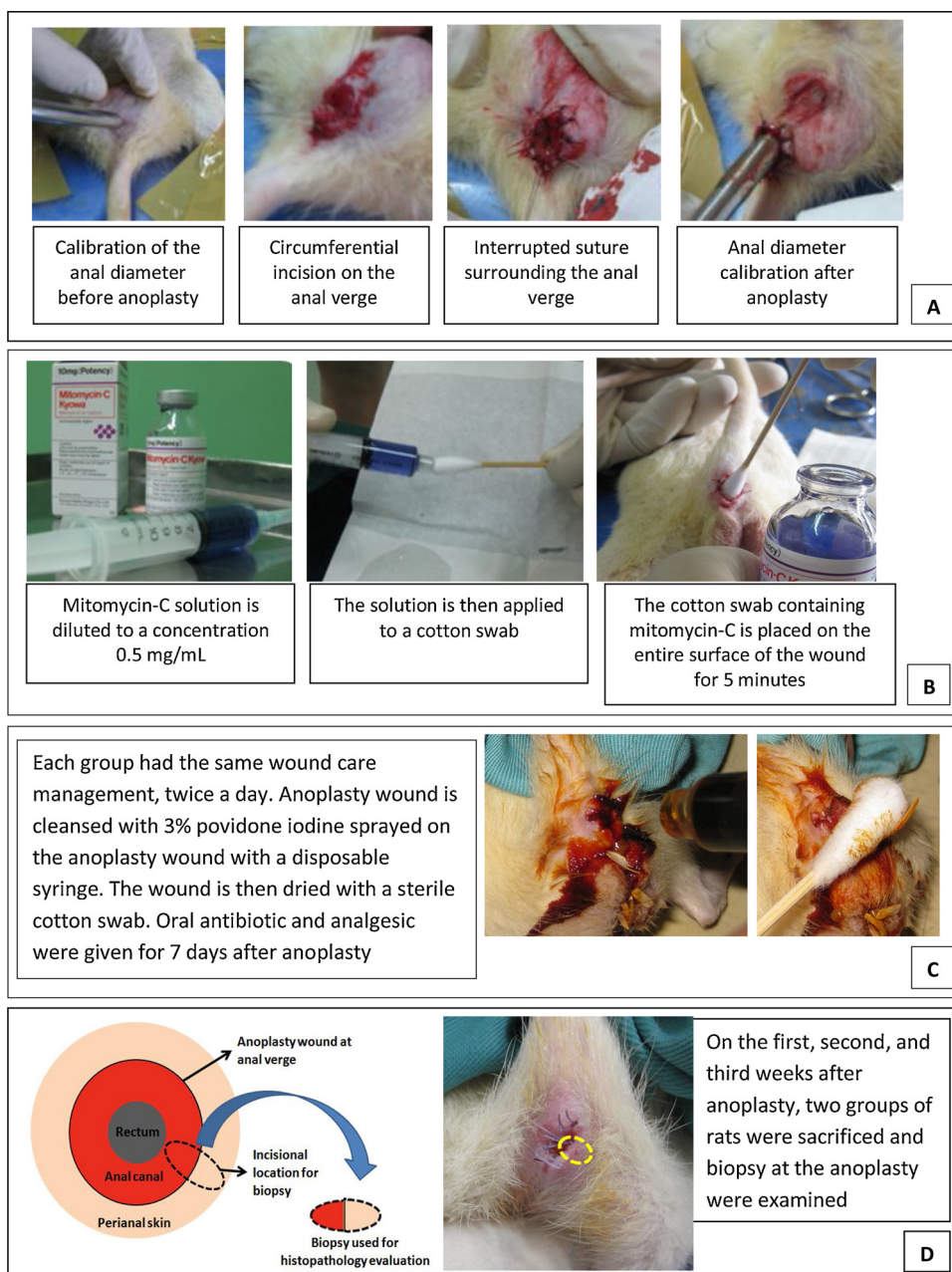
## 4. Discussion

In our study, we observed a significant decrease in the number of myofibroblasts in the treated group compared to the control group in the first week of observation. This finding is consistent with previous studies by Jester et al. [23] and Tawfik et al. [24], which were conducted at different animal models and different anatomical sites. The decrease of myofibroblasts in MMC treated group has raised concern to many researchers about the adverse effects of MMC in the wound healing process. Jester et al. [23] found that MMC induced DNA damage leading to abnormal myofibroblasts differentiation, proliferation, and gene transcription. Moreover, it was found that the DNA damage in MMC treated keratocytes leads to long-term effects on myofibroblasts differentiation and corneal repair in culture and animal wound healing models [23]. The ability of MMC to impair and delay wound healing was also reported by Gray et al [25]. This effect occurred due to the ability of MMC to block DNA synthesis and thus prevent long-term fibroblasts proliferation [25]. Hirshoren and Eliashar [1] revealed that the application of MMC might prolong the wound healing process by causing cartilage necrosis and vocal cord atrophy.

In this study, all of the anoplasty wounds had healed macroscopically by the first week after the surgical procedure. The number of myofibroblasts in the treated group increased and eventually resulted in the same score as the control group after two weeks. The exact mechanism by which MMC could suppress the myofibroblasts differentiation in the first week and then seems not to affect the myofibroblasts after two weeks remains unclear. Several possible explanations exist.

MMC can reduce the number of fibroblasts by suppressing fibroblasts proliferation without any effect on the migration or attachment [10]. These migrating fibroblasts might differentiate to myofibroblasts leading to the increase of myofibroblasts. Another possible reason is that the myofibroblasts did not solely derive from fibroblasts. Myofibroblasts have multiple cellular origins, including endothelial cells, smooth muscle cells, pericytes, epithelial cells, hepatic perisinusoidal cells, mesenchymal stem cells, and bone marrow-derived cells known as fibrocytes [16,26].

A study by Limat et al. [27] showed that MMC or x-ray treatment could accelerate the differentiation of postmitotic fibroblasts. This study showed that postmitotic human dermal fibroblasts obtained by MMC or x-ray treatment support the growth of cutaneous epithelial cells very efficiently *in vitro* [27]. Shephard et al. [28] used keratinocyte-fibroblast monolayer coculture to investigate the influence of keratinocytes on cocultured irradiated fibroblasts. It was revealed that



**Fig. 1.** Documentation of representative procedures used in the study. (A) Anoplasty procedure. (B) Application of topical mitomycin-C in treatment group. (C) Wound care procedures for both the control and treated groups. (D) Biopsy procedure for the histopathological evaluations.

**Table 1**  
Modified scoring system for total myofibroblast based on  $\alpha$ -SMA expression in immunohistochemical examinations.

Score	Intensity	Staining Area Percentage
0	No	No
1	Weak	Less than 10%
2	Weak	10–50%
3	Weak	More than 50%
4	Moderate	Less than 10%
5	Moderate	10–50%
6	Moderate	More than 50%
7	Strong	Less than 10%
8	Strong	10–50%
9	Strong	More than 50%

$\alpha$ -SMA = alpha smooth muscle actin.

**Table 2**  
Comparisons of the total myofibroblast between the treated and control groups during three weeks observation.

Observation Time	Group	n	Median	Range	p*
1st week	Treated	5	5.0	5–6	0.007
	Control	5	9.0	8–9	
2nd week	Treated	5	6.0	6–9	0.381
	Control	5	6.0	5–9	
3rd week	Treated	5	6.0	6–9	0.572
	Control	5	6.0	5–9	

Note: \*) p value obtained using Mann-Whitney test.

the irradiation blocked fibroblasts proliferation in a manner similar to MMC, but left their metabolic capacities mostly unchanged. It was also reported that increased gene expression of extracellular matrix

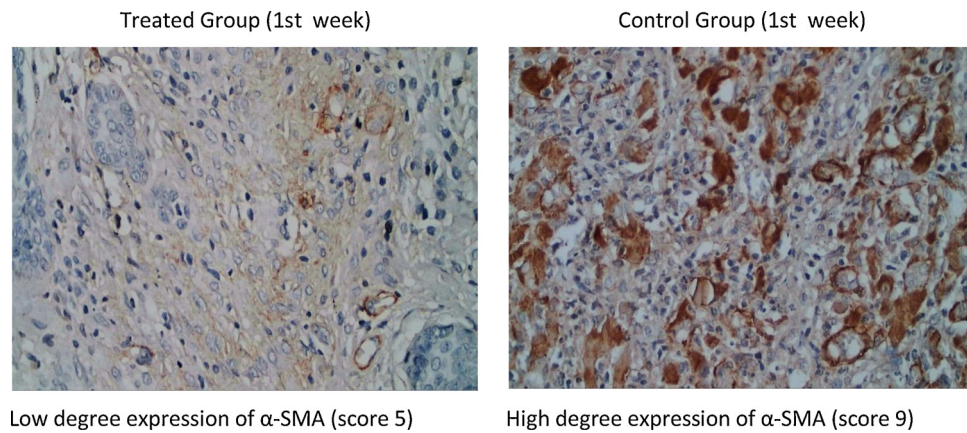


Fig. 2. Representative images from the immunohistochemical analysis of the treated and control groups in the first week where significant differences were observed.

constituents, such as several collagens, basement membrane proteins, various proteoglycans, glycoproteins, and enzymes were observed, which were associated with extracellular matrix processing and maturation [28].

The biological effect of topical MMC has been shown to be influenced by concentration and exposure time. Both increased concentration and exposure time might cause greater biological effects [25]. Our study used a concentration of 0.5 mg/mL and a single application of 5 min. All of these factors might contribute to the increasing numbers of myofibroblasts and the process of anoplasty wound healing over the time of this research.

Our observation for anoplasty wound healing process was conducted for three weeks after the surgical procedure because the wound healing processes of rats are faster than those of humans. Rats only require approximately 10–14 days to heal a wide-open wound [29–31]. Our study used sutured wounds, so we assumed the anoplasty wound healing process would be faster.

This study has shown that the application of MMC to anoplasty wounds in the Wistar rats resulted in reduced numbers of myofibroblasts. Such effect was only observed in the first week and no effect was observed in the consecutive weeks of observation. No adverse effects were found during the study. Our long-term aim is to eventually use MMC immediately after surgical procedures to prevent scar formation in postanoplasty wounds. Future studies would also be directed on the identification of possible adverse effects that might be caused by topical MMC on anoplasty wound healing, especially in the long term.

#### Funding source

This research did not receive any specific grant from funding agencies in the public, commercial, or not-for-profit sectors.

#### Conflict of interest

All authors declare no conflict of interest.

#### References

- [1] N. Hirshoren, R. Eliashar, Wound-healing modulation in upper airway stenosis-Myths and facts, *Head Neck* 31 (2009) 111–126, <https://doi.org/10.1002/hed.20925>.
- [2] M.K.S. Heran, R. Baird, G.K. Blair, E.D. Skarsgard, Topical mitomycin-C for recalcitrant esophageal strictures: a novel endoscopic/fluoroscopic technique for safe endoluminal delivery, *J. Pediatr. Surg.* 43 (2008) 815–818, <https://doi.org/10.1016/j.jpedsurg.2007.12.017>.
- [3] P. Betalli, F. De Corti, D. Minucci, R. Mazzarotto, L. Meneghini, G. Bisogno, G. Cecchetto, Successful topical treatment with mitomycin-C in a female with post-brachytherapy vaginal stricture, *Pediatr. Blood Cancer* 51 (2008) 550–552, <https://doi.org/10.1002/pbc.21641>.
- [4] S. Rosseanu, N. Afzal, B. Yerushalmi, E. Ibarguen-Secchia, P. Lewindon, D. Cameron, T. Mahler, K. Schwagten, H. K?hler, K.J. Lindley, M. Thomson, Topical application of mitomycin-C in oesophageal strictures, *J. Pediatr. Gastroenterol. Nutr.* 44 (2007) 336–341, <https://doi.org/10.1097/MPG.0b013e31802c6e45>.
- [5] M.B. Gillespie, T.A. Day, A.K. Sharma, M.B. Brodsky, B. Martin-Harris, Role of mitomycin in upper digestive tract stricture, *Head Neck* 29 (2007) 12–17, <https://doi.org/10.1002/hed.20476>.
- [6] A. Solomon, I. Kaiserman, F.D. Raiskup, D. Landau, J. Frucht-Pery, Long-term effects of mitomycin C in pterygium surgery on scleral thickness and the conjunctival epithelium, *Ophthalmology* 111 (2004) 1522–1527, <https://doi.org/10.1016/j.ophtha.2004.02.007>.
- [7] P.T. Khaw, E. Jones, K. Mireskandari, A. Dahlmann, A. Cambrey, Modulating wound healing after glaucoma surgery, *Glaucoma Today* (July/August) (2004) 12–19.
- [8] A. Ayyildiz, B. Nuhoglu, B. Gulerkaya, M. Caydere, H. Ustun, C. Germiyanoglu, D. Erol, Effect of intraurethral Mitomycin-C on healing and fibrosis in rats with experimentally induced urethral stricture, *Int. J. Urol.* 11 (2004) 1122–1126, <https://doi.org/10.1111/j.1442-2042.2004.00959.x>.
- [9] R. Rahbar, S.M. Shapshay, G.B. Healy, Mitomycin: effects on laryngeal and tracheal stenosis, benefits, and complications, *Ann. Otol. Rhinol. Laryngol.* 110 (2001) 1–6, <https://doi.org/10.1177/000348940111000101>.
- [10] D.A. Lee, Antifibrosis agents and glaucoma surgery, *Investig. Ophthalmol. Vis. Sci.* 35 (1994) 3789–3791.
- [11] C.M. Mueller, M. Beauoyer, D. St-Vil, Topical mitomycin-C for the treatment of anal stricture, *J. Pediatr. Surg.* 45 (2010) 241–244, <https://doi.org/10.1016/j.jpedsurg.2009.10.038>.
- [12] T.I. Kim, S.Y. Lee, J.H. Pak, H. Tchah, M.S. Kook, Mitomycin C, ceramide, and 5-fluorouracil inhibit corneal haze and apoptosis after PRK, *Cornea* 25 (2006) 55–60, <https://doi.org/10.1097/01.icc.0000167878.11687.9a>.
- [13] Y. Wang, J. Ren, K. Xia, S. Wang, T. Yin, D. Xie, L. Li, Effect of mitomycin on normal dermal fibroblast and HaCat cell: an in vitro study, *J. Zhejiang Univ. Sci. B* 13 (2012) 997–1005, <https://doi.org/10.1631/jzus.B1200055>.
- [14] G. Gabbiani, The myofibroblast in wound healing and fibrocontractive diseases, *J. Pathol.* 200 (2003) 500–503, <https://doi.org/10.1002/path.1427>.
- [15] R.J. McAnulty, Fibroblasts and myofibroblasts: their source, function and role in disease, *Int. J. Biochem. Cell Biol.* 39 (2007) 666–671, <https://doi.org/10.1016/j.biocel.2006.11.005>.
- [16] B. Hinz, S.H. Phan, V.J. Thannickal, M. Prunotto, A. Desmouliere, J. Varga, O. De Wever, M. Mareel, G. Gabbiani, Recent developments in myofibroblast biology: paradigms for connective tissue remodeling, *Am. J. Pathol.* 180 (2012) 1340–1355, <https://doi.org/10.1016/j.ajpath.2012.02.004>.
- [17] F. Klingberg, B. Hinz, E.S. White, The myofibroblast matrix: implications for tissue repair and fibrosis, *J. Pathol.* 229 (2013) 298–309, <https://doi.org/10.1002/path.4104>.
- [18] H.F. Lampus, D.D. Kusmayadi, B.A. Nawas, The influence of topical mitomycin-C on total fibroblasts, epithelialization, and collagenization in anoplasty wound healing in Wistar rats, *J. Pediatr. Surg.* 50 (2015), <https://doi.org/10.1016/j.jpedsurg.2015.03.059>.
- [19] T.I. Kim, J.H. Pak, S.Y. Lee, H. Tchah, Mitomycin C-induced reduction of keratocytes and fibroblasts after photorefractive keratectomy, *Investig. Ophthalmol. Vis. Sci.* 45 (2004) 2978–2984, <https://doi.org/10.1167/iovs.04-0070>.
- [20] A. Poortmans, J.J. Wyndaele, M. Levator ani in the rat: does it really lift the anus? *Anat. Rec.* 251 (1998) 20–27, [https://doi.org/10.1002/\(SICI\)1097-0185\(199805\)251:1<20::AID-AR5>3.0.CO;2-I](https://doi.org/10.1002/(SICI)1097-0185(199805)251:1<20::AID-AR5>3.0.CO;2-I).
- [21] M.F.W. Festing, V. Baumans, R.D. Combes, C.F.M. Hendriksen, B.R. Howard, P. David, G.J. Moore, P. Overend, M.S. Wilson, Reducing the use of laboratory animals in biomedical research: problems and possible solutions, *Altern. Lab. Anim.* 26 (1998) 283–301.
- [22] I. Watermann, B. Schmitt, F. Stellmacher, J. Müller, R. Gaber, C. Kugler, N. Reinmuth, R.M. Huber, M. Thomas, P. Zabel, K.F. Rabe, D. Jonigk, A. Warth, E. Vollmer, M. Reck, T. Goldmann, Improved diagnostics targeting c-MET in non-small cell lung cancer: expression, amplification and activation? *Diagn. Pathol.* 10 (2015) 1–12, <https://doi.org/10.1186/s13000-015-0362-5>.
- [23] J.V. Jester, C.J. Nien, V. Vasilou, D.J. Brown, Quiescent keratocytes fail to repair

- MMC induced DNA damage leading to the long-term inhibition of myofibroblast differentiation and wound healing, *Mol. Vis.* 18 (2012) 1828–1839 <http://www.pubmedcentral.nih.gov/articlerender.fcgi?artid=3398499&tool=pmcentrez&rendertype=abstract>.
- [24] H.A. Tawfik, M.H. Abdulhafez, Y.A. Fouad, H.O. Rashed, W.M. Osman, Revisiting the role of the Myofibroblast in socket surgery: an immunohistochemical study, *Ophthal. Plast. Reconstr. Surg.* 32 (2016) 292–295, <https://doi.org/10.1097/IOP.0000000000000510>.
- [25] S.D. Gray, N. Tritle, W. Li, The effect of Mitomycin on extracellular matrix proteins in a rat wound model, *Laryngoscope* 113 (2003) 237–242, <https://doi.org/10.1097/00005537-200302000-00008>.
- [26] B. Hinz, S.H. Phan, V.J. Thannickal, A. Galli, M.L. Bochaton-Piallat, G. Gabbiani, The myofibroblast: one function, multiple origins, *Am. J. Pathol.* 170 (2007) 1807–1816, <https://doi.org/10.2353/ajpath.2007.070112>.
- [27] A. Limat, T. Hunziker, C. Boillat, F. Noser, U. Wiesmann, Postmitotic human dermal fibroblasts preserve intact feeder properties for epithelial cell growth after long-term cryopreservation, *In Vitro Cell. Dev. Biol.* 26 (1990) 709–712 (Accessed 7 October 2018), <http://www.ncbi.nlm.nih.gov/pubmed/2384448>.
- [28] P. Shephard, G. Martin, S. Smola-Hess, G. Brunner, T. Krieg, H. Smola, Myofibroblast differentiation is induced in keratinocyte-fibroblast co-cultures and is antagonistically regulated by endogenous transforming growth factor- $\beta$ , and interleukin-1, *Am. J. Pathol.* 164 (2004) 2055–2066, [https://doi.org/10.1016/S0002-9440\(10\)63764-9](https://doi.org/10.1016/S0002-9440(10)63764-9).
- [29] P. Gal, R. Kilik, M. Mokry, B. Vidinsky, T. Vasilenko, S. Mozes, N. Bobrov, Z. Tomori, J. Bober, L. Lenhardt, Simple method of open skin wound healing model in corticosteroid-treated and diabetic rats: standardization of semi-quantitative and quantitative histological assessments, *Vet. Med. (Praha.)* 53 (2008) 652–659, <https://doi.org/10.17221/1973-VETMED>.
- [30] M.B. Girish, P.A. Patil, The influence of some azoles on wound healing in albino rats, *Indian J. Pharmacol.* 37 (2005) 247–250, <https://doi.org/10.4103/0253-7613.16572>.
- [31] N. Adamskaya, P. Dungal, R. Mittermayr, J. Hartinger, G. Feichtinger, K. Wassermann, H. Redl, M. Van Griensven, Light therapy by blue LED improves wound healing in an excision model in rats, *Injury* 42 (2011) 917–921, <https://doi.org/10.1016/j.injury.2010.03.023>.